

---

**Case Report**

# **Isolated Gallbladder Injury Due to Blunt Abdominal Trauma: A Case Report**

*Yu-Chen Cheng<sup>1</sup>, Pai-Chun Yen<sup>3,4</sup>, I-Ting Tsai<sup>2</sup>*

---

While blunt trauma-induced gallbladder injury is rare with a prevalence of only 2% in all patients undergoing laparotomy, the incidence of isolated traumatic gallbladder injury is even lower because of the frequent presence of other associated intra-abdominal injuries. We present a case of isolated gallbladder avulsion in an unrestrained driver of a vehicle with alcohol consumption. The diagnosis was based on imaging findings and later corroborated by surgery. Since gallbladder injury can be a difficult diagnosis to make, early detection with ultrasound and computed tomography (CT) is essential. Signs of gallbladder injury include a collapsed gallbladder with pericholecystic fluid or a hydroptic gallbladder with intraluminal hematoma. The treatment of gallbladder injury depends on the severity and pattern of injury. Contusion of the gallbladder can be observed, but surgery is necessary in case of perforation or traumatic cholecystitis.

**Keywords:** Abdominal trauma, Gallbladder injury, Computed tomography (CT), Ultrasound

---

## **Case Report**

A 36-year-old man was an unrestrained driver of a vehicle with alcohol consumption. The patient was transported to the Emergency Department by an ambulance with the presentation of a superficial facial laceration and a right upper abdominal abrasion. Initial vital signs showed a normal body temperature (36°C), an elevated blood pressure of 177/94 mmHg, and a pulse rate of 106/min. There was right upper abdominal tenderness on palpation without rebound tenderness or muscle guarding. The remainder of the physical examination was unremarkable. Laboratory findings

revealed an elevated hepatic enzyme level with a serum glutamic pyruvic transaminase (GPT) activity of 76 IU/L and a blood alcohol level of 296 mg/dL. An abdominal computed tomography (CT) was performed 3 hours later due to progressive right upper abdominal pain. CT scan of the abdomen demonstrated high-density changes in the gallbladder and pericholecystic fluid accumulation (Fig. 1). The liver, spleen, both kidneys, and duodenum showed no significant anomaly.

Under the diagnosis of gallbladder perforation, exploratory laparotomy was subsequently performed that revealed a non-perforated gallbladder avulsion with hematoma from the liver bed (Fig. 2) without gross hepatic

---

From the <sup>1</sup>Department of Diagnostic Radiology, <sup>2</sup>Department of Emergency Medicine, E-Da Hospital, I-Shou University Kaohsiung, Taiwan; <sup>3</sup>Chang Gung University College of Medicine, <sup>4</sup>Department of Emergency Medicine, Chang Gung Memorial Hospital, Kaohsiung, Taiwan.

Received: May 26, 2011

Accepted: July 28, 2011

Address reprint and correspondence to: Dr. Pai-Chun Yen, Department of Emergency Medicine, Kaohsiung Chang Gung Memorial Hospital, 123 Ta-Pei Road, Niao-Sung District, Kaohsiung Country, Taiwan, R.O.C.

Tel: +886-7-7317123 ext 8415, E-mail: arach0616@msn.com

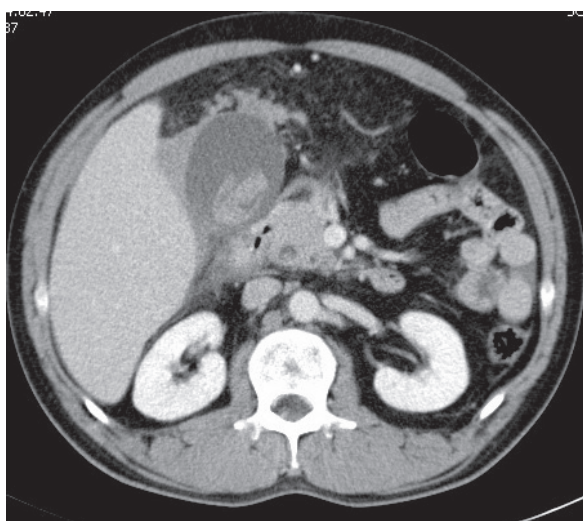


Fig. 1 Hydroptic gallbladder with intraluminal hematoma and pericholecystic fluid.

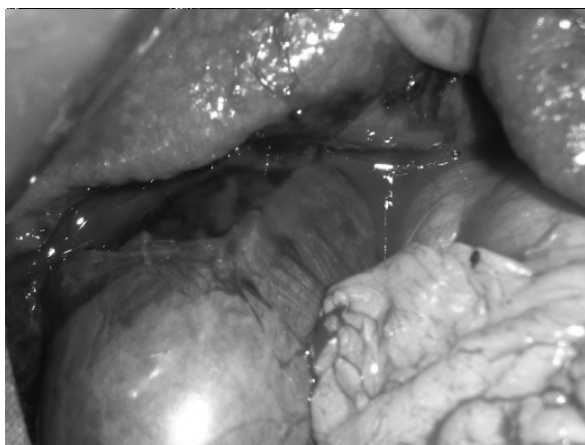

Fig. 2 Gallbladder avulsion with hematoma from liver bed.

injury. Further exploration of the abdomen showed neither injury to the hepatoduodenal ligament nor bile leak. Cholecystectomy was performed. The abdomen was cleaned, drained, and closed in layers. The patient's postoperative course was uneventful.

## Discussion

While most cases of gallbladder injury occur following penetrating trauma,<sup>1</sup> injury after blunt trauma is rare. Only 2% of patients undergoing laparotomy for blunt abdominal trauma showed evidence of gallbladder injury.<sup>2-6</sup> The incidence of isolated damage to the gallbladder is even lower. According to a review by Soderstrom et al.,<sup>7</sup> only 5 out of 30

cases of gallbladder injuries were isolated. The low incidence of gallbladder injury is attributed to the organ's well-protected location that also explains the high incidence of other associated intra-abdominal injuries if gallbladder injury is present.

Most blunt gallbladder injuries result from motor vehicle crashes, falls, and kicks or blows to the abdomen.<sup>8</sup> Factors predisposing to blunt gallbladder injuries are a thin-walled or distended gallbladder, and alcohol consumption that increases the tone of sphincter of Oddi and biliary tract pressure.<sup>3,8</sup>

Gallbladder injuries includes contusion, laceration, and avulsion, with the mechanism involving compressive and shearing forces seen most commonly in motor vehicle collisions.<sup>2,4,8-9</sup> Contusion, defined as intramural hematoma, is most often diagnosed at the time of laparotomy and is probably underreported. Perforation, also known as "rupture" or "laceration," is the most commonly reported injury. Avulsion, the second most commonly reported injury, has three subtypes: partial avulsion, in which the gallbladder is partially torn from the liver bed; complete avulsion, in which the gallbladder is completely torn from the liver bed but with intact cystic duct and artery; and total avulsion, in which the gallbladder lies free in the abdomen, torn from all attachments.<sup>3-5,8-9</sup>

Associated intra-abdominal injuries are very common in patients with traumatic gallbladder injury. The liver, duodenum, and spleen are most commonly involved, in decreasing order of frequency.<sup>3,8</sup> In our case, however, no evidence of other intra-abdominal injury was noted both on imaging studies and on surgical exploration.

Early diagnosis of gallbladder injury due to blunt abdominal trauma is essential but is difficult to establish. Although diagnostic peritoneal lavage has not been proven to be useful in detecting gallbladder trauma,<sup>7</sup> ultrasound and CT are appropriate diagnostic tools to detect gallbladder injuries.<sup>10-11</sup> CT findings

suggestive of gallbladder injury include ill-defined contour or thickening of gallbladder wall, a hydroptic gallbladder with an intraluminal inhomogenic fluid mass known as traumatic cholecystitis, active arterial extravasation into the lumen, and collapsed gallbladder lumen.<sup>2-5</sup> Pericholecystic fluid is the most common but less specific finding of gallbladder trauma.<sup>3</sup> Delayed imaging can be useful in differentiating true gallbladder hemorrhage from other non-traumatic gallbladder pathologies because of an increase in the amount of dense fluid or extravasation as the hemorrhage progresses.<sup>12</sup> If there are diagnostic difficulties in stable patients, laparoscopy may be considered. It is useful both as a diagnostic and a therapeutic tool. When laparoscopy does not give therapeutic success, it should be switched to laparotomy.<sup>13</sup> In our case, however, due to uncertainty of the diagnosis, an exploratory laparotomy was chosen as the safest option.

The treatment of gallbladder injury depends on the severity of the injury and the general condition of the patient. In cases of gallbladder rupture and major tears as complete or total avulsion, cholecystectomy is the recommended treatment. However, less severe injuries such as gallbladder contusion and isolated partial avulsion may be observed.<sup>4-5,7-8</sup>

In patients with blunt abdominal trauma, traumatic gallbladder injury is commonly associated with other intra-abdominal injuries that should always be taken into consideration. Isolated gallbladder injury allows conservative treatment as long as no

perforation or traumatic cholecystitis is present.

## References

1. Salzman S, Lutfi R, Fishman D, et al: Merlotti G. Traumatic rupture of the gallbladder. *J Trauma* 2006;61:454-6.
2. Wittenberg A, Minotti AJ: CT Diagnosis of traumatic gallbladder injury. *Am J Roentgenol* 2005;185:1573-4.
3. Chen X, Talner LB, Jurkovich GJ: Gallbladder avulsion due to blunt trauma. *Am J Roentgenol* 2001;177:822.
4. Erb RE, Mirvis SE, Shanmuganathan K: Gallbladder injury secondary to blunt trauma: CT findings. *J Comput Assist Tomogr* 1994;18:778-84.
5. Gupta A, Stuhlfaut JW, Fleming KW, et al: Blunt trauma of the pancreas and biliary tract: a multimodality imaging approach to diagnosis. *Radiographics* 24:1381-95.
6. Wong YC, Wang LJ, Chen CJ: MRI of an isolated traumatic perforation of the gallbladder. *J Comput Assist Tomogr* 2000;24:657-8.
7. Soderstrom CA, Maekawa K, DuPriest RW Jr, et al: Gallbladder injuries resulting from blunt abdominal trauma: an experience and review. *Ann Surg* 1981;193:60-6.
8. Sharma O. Blunt gall bladder injuries: presentation of twenty-two cases with review of the literature. *J Trauma* 1993;39:576-80.
9. Losanoff JE, Kjossev KT. Complete trauma avulsion of the gallbladder. *Injury* 1999;30:365-8.
10. Akay HO, Senturk S, Cigdem MK, et al: Isolated traumatic gallbladder rupture: US findings and the role of repeat US in diagnosis. *Pediatr Radiol* 2008;38:691-3.
11. Bindra PS, Dobbins JM, Novelline RA. Diagnosis of traumatic gallbladder avulsion: role of sagittal and coronal computed tomographic reformations. *Emerg Radiol* 1998;5:256-8.
12. Wittenberg A, Minotti AJ: CT diagnosis of traumatic gallbladder injury. *AJR* 2005;185:1573-4.
13. Kohler R, Millin R, Bonner B, et al: Laparoscopic treatment of on isolated gallbladder rupture following blunt abdominal trauma in a schoolboy rugby player. *Br J Sports Med* 2002;36:378-9.