
Case Report

Thyroid Abscess Causing Sternoclavicular Joint Infection and Mediastinitis

Shih-Hsien Yang¹, Po-Chih Chang^{2,3}, Yu-Jen Cheng¹, Yung-Chuan Lu⁴

We report a 47-year-old diabetic woman presenting with neck and upper chest pain for 6 days. Cervical computed tomography identified a thyroid abscess with extension to right upper chest wall, right sternoclavicular joint, and superior-anterior mediastinum. Subsequent echo-guided aspiration confirmed the diagnosis. Culture yielded mixed infection of *Streptococcus viridans* and *Peptostreptococcus micros*. It was treated successfully with extensive surgical debridement, broad-spectrum antibiotics and good glycemic control. This case report highlights a rare presentation of thyroid abscess with mediastinum, chest wall, and sternoclavicular joint involvement. An early recognition, prompt surgical debridement with supportive medical management could result in a satisfactory outcome.

Key words: chest wall abscess, mediastinitis, sternoclavicular joint infection, thyroid abscess

Introduction

Thyroid abscess is extremely rare and is usually a consequence of acute suppurative thyroiditis. Cervical esophageal perforation, pyriform sinus fistula or trauma may predispose to this intractable condition.¹ Thyroid abscess associated with mediastinitis, sternoclavicular joint infection, or chest wall abscess has rarely been reported.² Herein, we report the case of a patient with thyroid abscess with subsequent involvement of sternoclavicular joint and chest wall.

Case Report

A 47-year-old woman presented with a 6 day history of painful right neck swelling with subsequent tenderness in the right upper-medial chest. She also complained of painful swallowing and slight limitation of right shoulder range of motion. The patient had a past history of uncontrolled diabetes mellitus (DM) for 3 years (glycated hemoglobin: 12.4%) and hypertriglyceridemia (337 mg/dL). She denied any unusual childhood diseases or recent interventional procedures. She also had no

From the ¹Division of Thoracic Surgery, and ²Division of General Surgery, and ³Bariatric and Metabolic International Surgery Center, and ⁴Division of Endocrinology and Metabolism, E-Da Hospital, I-Shou University, Kaohsiung, Taiwan.

Received: January 22, 2015

Accepted: June 12, 2015

Address reprint request and correspondence to: Po-Chih Chang, Division of General Surgery, and Bariatric and Metabolic International Surgery Center, E-Da Hospital, No. 1, Yida Road, Jiaosu Village, Yanchao District, Kaohsiung City 82445, Taiwan.

Tel: +886-7-6150011 ext. 3036, Fax: +886-7-6155352, E-mail: dr.changpochih@hotmail.com

history of tuberculosis, neck trauma, thyroid disease, or any intake of sharp or hard food (i.e., fish bone). She was a teetotaler, too. At the emergency department, physical examination revealed fever (38.4°C), cervical and right upper-medial chest wall inflammation (local tenderness, erythema, and swelling). Laboratory reports showed leukocytosis (12,520/ μ L), elevated level of C-reactive protein (136.9 mg/L), and a blood glucose level of 285 mg/dL. The thyroid function test showed a euthyroid status (free thyroxine 1.09 ng/dL (normal range 0.7-1.48); TSH 2.21 μ IU/mL (normal range 0.35-4.94). Computed tomography (CT) of the neck and chest revealed a huge, heterogeneous cystic lesion in the right thyroid lobe with extension to right sternoclavicular joint, superior part of anterior mediastinum, and chest wall (Fig. 1). No obvious airway compression was identified. The thyroid ultrasound demonstrated a mixed-echogenic lesion over the right thyroid lobe with ill-defined margin (Fig. 2). Fine-needle aspiration drained 10 mL of pus and the cytology showed high numbers

of polymorphonuclear leucocytes, which was compatible with thyroid abscess. She was taken up for urgent surgical intervention to prevent any septic sequelae, given her immunocompromised status due to uncontrolled DM. At surgery, frank pus over right thyroid lobe, right upper-medial chest wall, right sternocostoclavicular joint, and superior-anterior mediastinum was noted. We performed complete evacuation of pus with right subtotal thyroidectomy, right sternoclavicular joint resection, and chest wall and mediastinal debridement. Procedure was uneventful and we were able to close the wound was primarily without the need of reconstructive maneuvers. Subsequent esophagogram and laryngoscopic examination did not show any residual swelling or hypopharyngeal fistula. She was put on empirical antibiotics (amoxicillin/clavulanic acid) for 14 days. Physician consultation was done for glycemic control and advice followed. The initial acid-fast stain for *Mycobacterium spp* was negative. Pus culture yielded mixed infection of *Streptococcus viridans* (susceptible to Clindamycin,

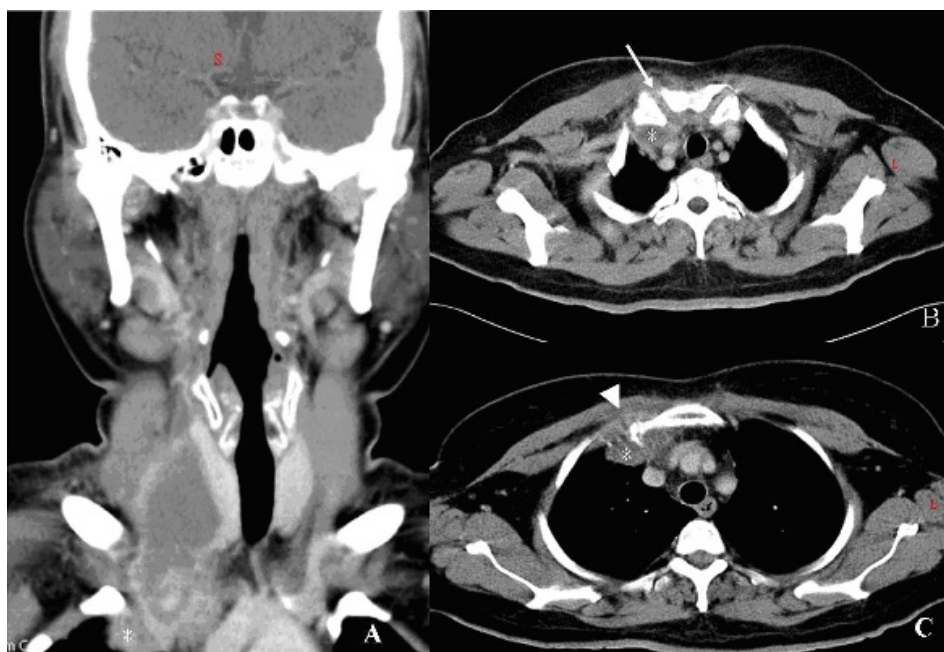


Fig. 1 (A) The coronal computed tomography (CT) of the neck revealed a thyroid abscess, measuring 35 × 29 × 71 mm in size, with local phlegmon formation and extension to superior-anterior mediastinum (asterisk). (1B and C) The axial chest CT showed concomitant sternoclavicular joint infection with intra-articular joint involvement (arrow), mediastinitis (asterisk), and chest wall abscess (arrowhead).

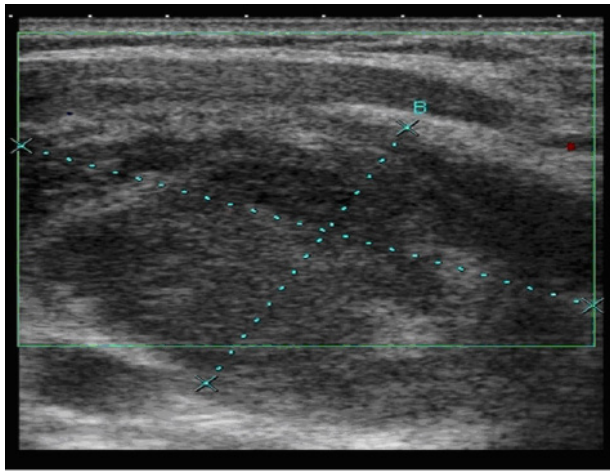


Fig. 2 The thyroid ultrasound demonstrated a mixed-echogenic lesion at the right thyroid lobe with ill-defined margin, compatible with thyroid abscess with outward extension.

Erythromycin and Vancomycin) and *Peptostreptococcus micros* (susceptible to cindamycin, flomoxef and penicillin). *Mycobacterium tuberculosis* was not isolated eventually. Pathological examination also confirmed acute suppurative inflammation of the thyroid gland with presence of osteochondroid tissue. The patient had an uneventful post-operative course without any restriction in shoulder range of movements. She was discharged from hospital on post-operative day 15.

Discussion

The thyroid gland is clinically resistant to infection because of its rich blood supply, lymphatic drainage, prominent iodine content, and fibrous anatomical capsule.^{1,3} Thyroid abscess is a rare thyroid pathology that usually results from acute suppurative thyroiditis with abscess formation or by hematogenous spread from different foci of infection, a pre-existing pyriform sinus tract infection, recent upper respiratory tract infection or nodular goiter.¹ It often presents with acute onset of painful cervical swelling, fever, dyspnea, dysphagia or odynophagia. It may manifest with chest pain due to downward extension to the superior-anterior mediastinum. Rarely it may lead to

necrotizing mediastinitis. To the best of our knowledge, a thyroid abscess with concomitant mediastinal, chest wall, and sternoclavicular joint involvement has never been reported.²

We surmise that purulent fluid descending from the thyroid abscess directly infiltrated the superior mediastinum, tracked along the prevascular space, and ultimately led to sternoclavicular joint infection and chest wall abscess in our patient.

Cervical CT remains the “gold standard” for definite diagnosis in emergency situations and can provide images of the infected structures in the deep neck region.^{1,2} A subsequent esophagogram or laryngoscopic examination to exclude a possible remnant pyriform sinus tract is mandatory; if such a tract is found, a thorough excision of it will be necessary for complete evacuation of the thyroid abscess and prevent relapse.¹ However, as for our case, no remnant pyriform sinus tract was identified at that time. An immunocompromised condition due to uncontrolled diabetes may have predisposed the patient to the thyroid abscess formation.¹ Microbiological result (*Streptococcus viridans* and *Peptostreptococcus micros*), is suggestive of an occult dental caries or periodontal infection as the cause of thyroid abscess in our patient.⁴ In general, patients with limited diseases usually respond well to broad-spectrum antibiotics and incisional drainage or echo-guided aspiration; however, unilateral subtotal or total thyroidectomy is necessary for those refractory to antibiotic treatment or having an extra-capsular extension.^{1,3} For those with contiguous structures involvement, such as mediastinum (which might be indicative of a relatively immunocompromised condition), an extensive surgery with unilateral thyroidectomy and mediastinal debridement is necessary.² As our patient had mediastinitis, chest wall abscess, and intra articular involvement of right sternoclavicular joint with uncontrolled diabetes, we favored a thorough procedure with sternoclavicular joint resection and

adequate debridement to prevent a possible residual abscess and septic sequelae.^{5,6,7}

In conclusion, this case report highlights the rare but important possibility of thyroid abscess extending into the mediastinum, chest wall and sternoclavicular joint in a diabetic patient. An early recognition, prompt diagnosis and surgical debridement with supportive antibiotics and good glycemic control is essential for satisfactory outcomes.

References

1. Herndon MD, Christie DB, Ayoub MM, et al: Thyroid abscess: case report and review of the literature. *Am Surg* 2007;73:725-8.
2. Iwama S, Kato Y, Nakayama S: Acute suppurative thyroiditis extending to descending necrotizing mediastinitis and pericarditis. *Thyroid* 2007;17:281-2.
3. Ilyin A, Zhelonkina N, Severskaya N, et al: Nonsurgical management of thyroid abscess with sonographically guided fine needle aspiration. *J Clin Ultrasound* 2007;35:333-7.
4. Kuriyama T, Karasawa T, Nakagawa K, et al: Bacteriology and antimicrobial susceptibility of gram-positive cocci isolated from pus specimens of orofacial odontogenic infections. *Oral Microbiol Immunol* 2002;17:132-5.
5. Puri V, Meyers BF, Kreisel D, et al: Sternoclavicular joint infection: a comparison of two surgical approaches. *Ann Thorac Surg* 2011;91:257-61.
6. Pereira O, Prasad DS, Bal AM, et al: Fatal descending necrotizing mediastinitis secondary to acute suppurative thyroiditis developing in an apparently healthy woman. *Thyroid* 2010;20: 571-2.
7. Ross JJ, Shamsuddin H: Sternoclavicular septic arthritis: review of 180 cases. *Medicine (Baltimore)* 2004;83:139-48.