Brief Communication

DOI: 10.6966/EDMJ.202103_8(1).0004

Clinical Course of Gianotti-Crosti Syndrome (Papular Acrodermatitis)

*Ping-Hong Chen, Chen-Hao Lee, Yu-Tsun Su, Li-Min Chen**

Gianotti-Crosti syndrome (GCS), otherwise known as papular acrodermatitis, is a common skin disorder that most often occurs in young children. In spite of its benign prognosis, failure to recognize GCS could lead to unnecessary overtreatments and waste of medical resources. Herein, we present a case of GCS including an initial presentation and following changes of skin lesions. In conclusion, GCS should be taken into consideration if non-itchy papules over extremities were noted in young children.

Key words: Gianotti-Crosti syndrome, papular acrodermatitis, rash, children

Brief History

A three-year-five-month-old fully-vaccinated boy presented with a history of general rash for one week. He recently had a common cold two weeks before this presentation. Around one week prior to presentation, a papulovesicular rash developed over bilateral antecubital and popliteal fossae with a mild itching sensation, which then spread to his face and trunk one day later. He had no known history of allergy or recent insect bites.

On presentation, he was afebrile. Pink papules (all flat-topped and monomorphic) were noted over face, trunk, and extremities (sparing the palms and soles of hands and feet) (Fig. 1). His mucosal surfaces and nails were intact. Routine blood tests were unremarkable. Four days later, the lesions coalesced into plaques with lichenification (Fig. 2). Three weeks after the initial presentation, the plaques diminished and desquamation predominantly over limbs ensued (Fig. 3). Viral cultures of his throat yielded no growth.

Discussion

The findings in this case are characteristic of Gianotti-Crosti syndrome (GCS), also called papular acrodermatitis. The actual incidence of GCS is difficult to estimate because it is

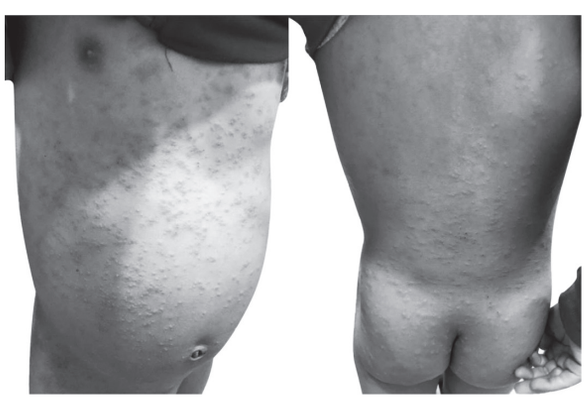

Fig. 1 Day 1: Patient presentation to the emergency room. The rash spread to face and trunk one day after papular rash developed over bilateral elbows and popliteal fossae.

From the Department of Pediatrics, E-Da Hospital, I-Shou University, Kaohsiung,Taiwan
Received: July 31, 2019 Accepted: May 12, 2020
* Address reprint request and correspondence to: Li-Min Chen, Department of Pediatrics, E-Da Hospital, No.1, Yida Road, Jiaosu Village, Yanchao District, Kaohsiung City, 82445, Taiwan
Tel: +886-7-615-0011 ext. 252348, Fax: +886-7-615-0940

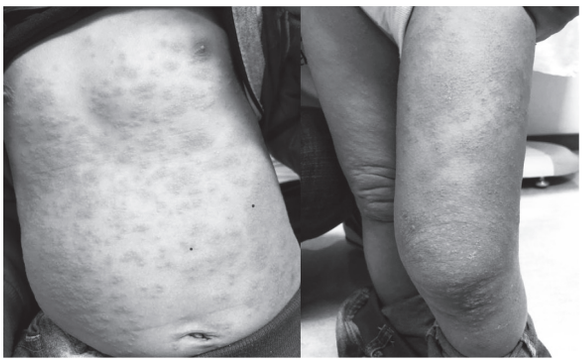

Fig. 2 Four days later at outpatient clinic, the lesions coalesced into plaques with lichenification.

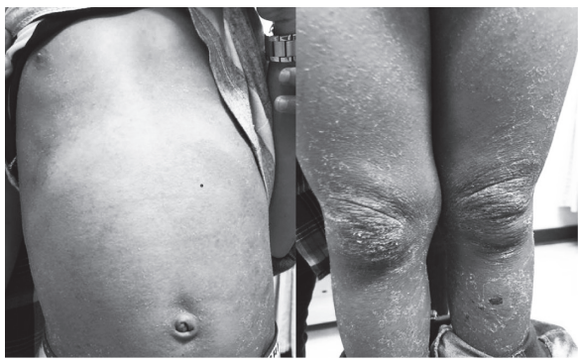

Fig. 3 Three weeks after initial presentation, the reddish plaque diminished, only general desquamation, dominantly over limbs.

profoundly underdiagnosed.[1] GCS primarily affects children between three months and 15 years of age. The etiology of GCS is unknown. However, it has been associated with viral infections, most commonly with hepatitis B virus and Epstein-Barr virus.[3,4]

GCS usually erupts suddenly, sometimes with a prodrome of viral illness. The classic finding is symmetric acral papules, however involvement of the trunk is not uncommon (as in our case). The lesions are monomorphic papules or papulovesicles, 1 to 10 mm in diameter, which can be slightly pruritic and can become confluent.[2] The mucosal surfaces and nails are usually not involved. The clinical course can last ten days to six months.

The diagnosis is made clinically. Important differential diagnoses include varicella, scabies, hand-foot-and-mouth disease, and papular urticaria. Misdiagnosis can lead to unnecessary blood tests and medications. The management includes supportive care and reassurance about the benign nature.[5]

Statement of Financial Support

This work was supported by grants from E-Da Hospital (EDAHP107033).

References

1. Brandt O, Abeck D, Gianotti R, et al: Gianotti-Crosti syndrome. J Am Acad Dermatol 2006;54:136-45. doi: 10.1016/j.jaad.2005.09.033.
2. Chuh AAT: Gianotti-Crosti syndrome (papular acrodermatitis). In: Post TW ed. UpToDate. Waltham, MA: UpToDate, 2019.
3. Chuh A, Zawar V, Sciallis GF, et al: The diagnostic criteria of pityriasis rosea and Gianotti-Crosti syndrome - a protocol to establish diagnostic criteria of skin diseases. J R Coll Physicians Edinb 2015;45:218-25. doi: 10.4997/JRCPE.2015.310.
4. Balevicienė G, Maciulevicienė R, Schwartz RA: Papular acrodermatitis of childhood: the Gianotti-Crosti syndrome. Cutis 2001;67:291-4.
5. Magyarlaki M, Drobnitsch I, Schneider I: Papular acrodermatitis of childhood (Gianotti-Crosti disease). Pediatr Dermatol 1991; 8:224-7. doi: 10.1111/j.1525-1470.1991.tb00865.x.